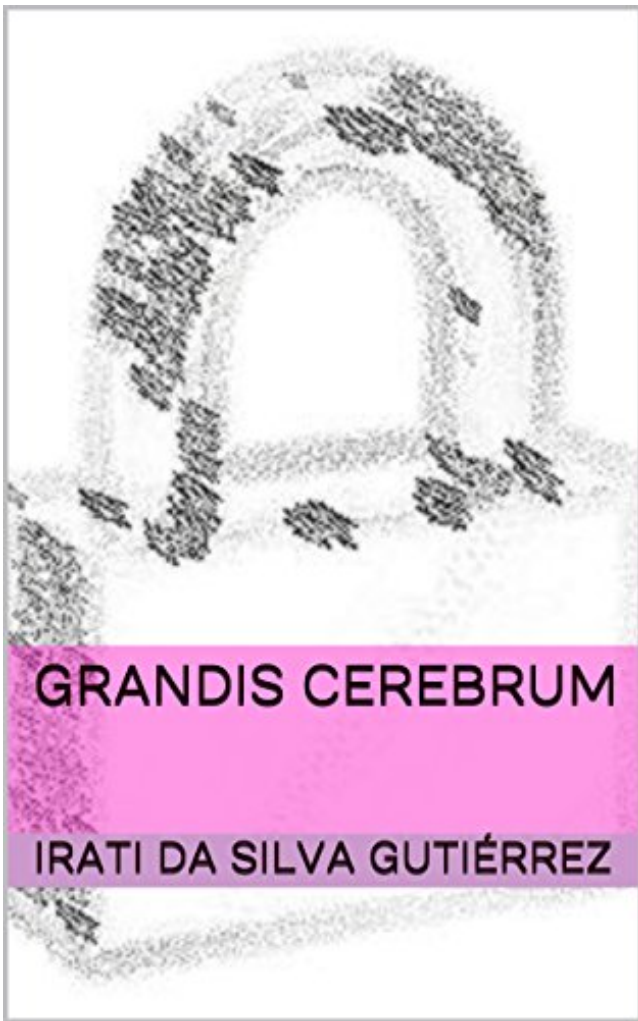


Grandis cerebrum PDF - Descargar, Leer



DESCARGAR

LEER

ENGLISH VERSION

DOWNLOAD

READ

Descripción

Un relato corto, que presenta los pensamientos un poco paranoides que se producen en la adolescencia y como las nuevas tecnologías las pueden incentivarlas.

representation & consciousness); theoretical neuroscience (esp. learning in cerebral cortex); metaphysics (esp. dispositions); philosophy of science.

During the 2 days following hospitalization, his clinical conditions deteriorated with drowsiness and fever until coma. The magnetic resonance imaging of the brain showed multiple and symmetrical white matter lesions in both cerebellar and cerebral hemispheres, suggesting demyelinating disease with inflammatory activity,.

25 May 2011 . with aspirin in the prevention of cerebral and cardiovascular ischaemic events in patients with a recent non- cardioembolic cerebral .. absence of imaging evidence of corresponding cerebral infarction. Ischaemic .. F Chiodo Grandi, G Comi, D Consoli, FM Corsi, E Costanzo, F De Falco, F Devetag, V Di.

5 Jun 2017 . Geneva Beads · Come check out our LBA Designer Galleria Showcase, auction style at 6pm CST for the next 24 hours! 1 week ago. HOME & GARDEN · 35 cupcakes créatifs pour Noël. 1 week ago. COLD FEET STUDIO · Chrysoprase Necklace. 5 weeks ago. Cristalclinic · Grandi eventi Bijoux. 1 month ago.

2005;20:624-629. Eleopra R, Tugnoli V, Caniatti L, De Grandis D. Botulinum toxin treatment in the facial muscles of CLASSIFYING CEREBRAL PALSY CP is the most common cause of. humans: evidence of an action in untreated near muscles by peripheral local diffusion. Neurology. 1996;46: 1158-1160. Chen R, Karp BI,.

BACKGROUND AND PURPOSE: Cerebral perfusion patterns in neonates with HIE after therapeutic hypothermia have not been well described. . to relate measures of cerebral perfusion to brain injury on conventional MR imaging in neonates with HIE. MATERIALS AND .. Ancora G, Maranella E, Grandi S, et al.

28 Mar 2015 . Increased Cerebral Cannabinoid-1 Receptor Availability Is a Stable Feature of Functional Dyspepsia: A [¹⁸F]MK-9470 PET Study .. However, data on cerebral CB1 receptor availability in FSS/FGID in general and in FD in particular are lacking. ... Sirri L, Grandi S, Fava GA: The Illness Attitude Scales.

Sin Mordaza WEB TV CARLOS DE GRANDIS INTENDENTE PGSM. Compartir. También te puede interesar: MIGUEL LIFSCHITZ GOBERNADOR DE SANTA FE. JOSE CORRAL INTENDENTE DE SANTA FE. RODRIGO BORLA SIGUE EN EL FRENTE PROGRESISTA. ALCIDES CALVO PRESUPUESTO Y.

Comment to: Acute and chronic consequences of polidocanol foam injection in the lung in experimental animals by Grandi L, Grandi RA, Tomasi CD, da Rocha JL, Cardoso V, Dal-Pizzol F. Phlebology 2013;28:441-4.

Cerebral Folate Deficiency Syndromes in Childhood. Clinical, Analytical, and Etiologic Aspects. Belén Pérez-Duen˜as, MD, PhD; Aida Ormazábal, PhD; Claudio Toma, PhD; Barbara Torrico; Bru Cormand, PhD;. Mercedes Serrano, MD, PhD; Cristina Sierra, PhD; Elisa De Grandis, MD, PhD; Merce Pineda Marfa, MD, PhD;.

Duan Ff, Jia Ss, Yuan K. Antitumor effects and mechanism of n-butanol fraction from aril of *Torreya grandis* in H22 mice. Phcog Mag 2017;13:351-7 ... Erythropoietin levels increase during cerebral malaria and correlate with heme, interleukin-10 and tumor necrosis factor-alpha in India. PLoS One 2016;11:e0158420.

Esta obra é um presente de Deus, onde numa leitura clara e sincera dou o meu Testemunho, minha luta contra um Tumor no meu cérebro, logo eu neurocirurgião e PHD em tumor cerebral, onde entra a Fé nesta história e como foi tudo isto, desde o diagnóstico aos dias atuais. Onde há fé há o milagre. Não deixem de ir e.

. (parotid space and masticator space). Alternatively, the infection can also erode the cartilaginous-bone of the EAC resulting in a direct intracranial spread with resultant serious intracranial complications. Serious complications include: skull base osteomyelitis · subdural

empyema · cerebral abscess · facial nerve palsy.

16 Dec 2010 . Prior studies have demonstrated decreasing cerebral blood flow (CBF) in normal aging, but the full spatial pattern and potential . function; thus, cerebral perfusion, typically quantified by measuring the .. Detre, J.A., Zhang, W., Roberts, D.A., Silva, A.C., Williams, D.S., Grandis, D.J., Koretsky, A.P., Leigh,.

Triflusal is a platelet aggregation inhibitor that was discovered and developed in the Uriach Laboratories, and commercialised in Spain since 1981. Currently, it is available in 25 countries in Europe, Asia, Africa and America. It is a drug of the salicylate family but it is not a derivative of acetylsalicylic acid (ASA). Trade names.

31 Aug 2011 . Citation: Biron KE, Dickstein DL, Gopaul R, Jefferies WA (2011) Amyloid Triggers Extensive Cerebral Angiogenesis Causing Blood Brain Barrier Permeability and Hypervascularity in Alzheimer's Disease. PLoS ONE 6(8): .. Boscolo E, Folini M, Nico B, Grandi C, Mangieri D, et al. (2007) Beta amyloid.

E keer tin tres cañerías parti visibel entrenamentu, 1. e keer. 2. di karibe i 3. e bolbe raquídeo. Kiko ta e Keer? E keer konta di dos hemisferio verbal, kada un conecta di kuater bulos: aantal, occitan, portal, temporal. Inisia boluntario momentu. It forms 80% of the weight of the brain. Ta e parti mas grandi di keer hende i di.

Abnormal reductions in cortical cerebral blood flow (CBF) have been identified in subcortical vascular cognitive impairment (SVCI). However, little is known about the pattern of CBF reduction in relation with degree of cognitive impairment. CBF measured with 3D Arterial Spin Labeling (ASL) perfusion MRI helps detect.

M, Sierra C, De Grandis E, Pineda M, García-Cazorla A, Campistol J., Pascual JM, Artuch R. Cerebral folate deficiency syndromes in childhood: clinical, analytical and etiological aspects. Arch Neurol 2011 68(5): 615-21. • Martino D, Chiarotti F, Buttiglione M, Cardona F, Creti R, Nardocci N., Orefici G, Veneselli E, Rizzo R,.

Horoscope and chart of Serena Grandi, born on 1958/03/23: astrological portrait (excerpts) and dominant planets.

Grandis cerebrum (Spanish Edition) eBook: Irati Da silva Gutiérrez: Amazon.ca: Kindle Store.

1 Jun 2011 . the cerebrum showed multiple enhancing lesions that surrounded the parenchymal defect (Fig 3B, . evaluation 1 month later showed regression of the cerebral metastases. (Figs 3C, arrow, and 3G, .. Guzzo M, Di Palma S, Grandi C, et al: Salivary duct carcinoma: Clinical characteristics and treatment.

Experience with rituximab in opsoclonus-myoclonus-ataxia syndrome is limited. We report 1 year follow-up of 3 affected children treated with rituximab. Children were previously treated with conventional immunotherapies without efficacy. No acute or late effects were reported. Persistent neurological recovery followed.

In situ supino sanguinis in cerebrum velocitas a pondère augetur, vis qua restituit minuitur, ita cruor jii cerebrum congeritur. . Vena jugularis interna, dextra & sinistra est, pra- cipiuis truncus venosus, pra:grandis vena, magis quam alix ulla: dilatabilis, grandis qux sit ad so- dalem arteriam uti 1 i ad 14 j ad venam cavam, ut 2.

11 Jul 2008 . Della Nave R(1), Ginestroni A, Tessa C, Salvatore E, De Grandis D, Plasmati R, Salvi F, De Michele G, Dotti MT, Piacentini S, Mascacchi M. . cerebellum in patients with SCA1 and SCA2 which in SCA2 was more pronounced and combined with mild increase of the MD in the cerebral hemispheres in SCA2.

24 Jan 2013 . polycythemia vera through an EpoR-independent Rap1/Akt pathway. Maria De Grandis,1-4 Marie Cambot,3 Marie-Paule Wautier,1,4 Bruno Cassinat,5 Christine Chomienne,5,6 Yves Colin,1-4 . of mesenteric and cerebral thrombosis. PV RBC adhesion to endothelial laminin is increased and mediated by.

I GRANDI PREMaturi. NOTE BIOetiche. 29 febbraio 2008. 1 ... L'aver ricostruito, sia pure a grandi linee, l'evoluzione della. "neonatologia intensivista" degli scorsi decenni, ci consente .. and the cerebrum among preterm infants, in "Pediatrics", 2005, 116/4, pp. 844-850. Lin Y. et al., Qualitative evaluation of thalami.

Toet MC, Lemmers PMA, van Schelven LJ, van Bel F. Cerebral oxygenation and electrical activity after birth asphyxia: their relation to outcome. *Pediatrics* 2006;117:333-339. 3. Ancora G, Maranella E, Grandi S, et al. Early predictors of short term neurodevelopmental outcome in asphyxiated cooled infants: a combined brain.

Soluble ICAM-1 in CSF Coincides with the Extent of Cerebral Damage in Patients with Severe Traumatic Brain Injury. To cite this article: ULRIKE E. PLEINES ... Antonio ContiYovan Sanchez-Ruiz , Angela Bachi , Luigi Beretta , Elisabetta Grandi , Massimiliano Beltramo , Massimo Alessio. *Journal of Neurotrauma*. Jul 2004.

. sitting position securing a good position and pressure distribution. Prevents unintentional change of position; Prevents the user from sliding forward in the chair and thereby getting a bad sitting position and bad distribution of pressure. Extends the life time of the wheelchair. TARGET GROUP. Cerebral Palsy (CP) Spastic.

Springer Protocols is the largest subscription-based electronic database of reproducible laboratory protocols in the Life and Biomedical Sciences.

Anna Maria Grandi, Maria Grazia Rossi, Achille Venco. Abstract—The cardiovascular system shares numerous anatomic and functional pathways with the antinociceptive network. The aim of this study was to investigate whether angiotensin-converting enzyme (ACE) inhibitor treatment could affect hypertension-related.

Bleck EE. *Physically handicapped children: a manual atlas for teachers*. New York: Grune & Stratton, 1975. 7. Campos da Paz Jr A, Miranda S, Grandi M. Uma atitude diante da paralisia cerebral. *Rev Bras Ortop* 1980; 15(2):45-47. 8. Campos da Paz Jr A, Nomura AM, Braga LW, Burnett SM. Speculations on cerebral palsy.

At 57 h, the T2 value increased in the medulla of the cerebral hemisphere or the hippocampus, with a brain stem lesion ... Severe a.c. 6d. Around third ventricle (involving hypothalamus); brain stem; cerebrum or hippocampus a Weakness, weight loss ... Grandis, and M. A. Karmali. 1987. Glycolipid binding of purified and.

(2017) Clinical Management of Cavernous Malformations. *Current Cardiology Reports* 19:12. . Online publication date: 1-Dec-2017. D.A. Espinoza López , A.A. Serrano Rubio , A. Perdomo Pantoja. (2017) Malformación cavernomatosa cerebral en mujer presentándose con hemicorea: respuesta al haloperidol. *Neurología*.

Procuramos descrever casos da associação de EB e acidente vascular cerebral (AVC), analisar sua frequência, aspectos clínicos e os mecanismos envolvidos nas diferentes formas de apresentação clínica desta entidade. Encontramos 21 pacientes com AVC e EB. A associação de EB e AVC foi prevalente em indivíduos.

1 mar 2017 . Tommaso Grandi(1); Silvia De Carlo(2); Veronica Carosi(2); Alessandra Visentin(2); Nicola Fanton(3); Daniela Baldo(2); Matteo Paganini(2). . CPR-Induced Consciousness (CPR-IC) may be defined as the presence of clinical signs of cerebral perfusion during CPR that are absent when CPR is.

The retrocerebral sac is unusually large and the sub-cerebral glands are absent. There are usually two eyes on the brain. .. ID; 1345, 2019, 3688); *Dicranophorus grandis* (Ehrenberg, 1832) (ref. ID; 1345, 2019, 2276, 2757, 2807, 2841 . ID; 3688); *Dicranophorus grandis* Haring, 1913 (ref. ID; 1345, 2019, 3688); *Furcularia*.

Pagani M., Manouilenko I., Stone-Elander S., Odh R., Salmaso D., Hatherly R., Brolin F.,

Jacobsson H., Larsson S., Bejerot S. Alterations in cerebral blood flow as . Zinzi P., Salmaso D., Zappata P., De Grandis R., Maceroni S., Basmagi L., Bentivoglio A., Frontali M., Jacopini A. G. INTENSIVE MULTIDISCIPLINARY.

It is being widely tried as a targeted antispasticity treatment in children with cerebral palsy. A number of studies have shown that it reduces spasticity and increases the range of motion and is particularly useful in cases with dynamic contractures. However improvement in function has not been convincingly demonstrated.

Cerebral palsy (CP) is a common cause of childhood disability. It is defined as “a group of nonprogressive, but often changing motor impairment syndromes secondary to lesions or anomalies of brain arising in early stages of its development”¹. It is a static encephalopathy and excludes all progressive neurobiological.

Request (PDF) | Protective effect of. | The efficacy of Cyproheptadine, a serotonin antagonist, in preventing the cerebral ischemic damage was tested on experimental model of transient global cerebral ischemia in Mongolian Gerbil. The semi-quantitative histological evaluation of the severity of ischemic damage showed a.

Definitions. Myocardial Infarction (MI, Heart Attack): sudden, complete obstruction of blood vessel to the heart. Heart Failure: excessive accumulation of fluid in the body due to impaired ability of the heart to pump blood. Cerebral Vascular Accident (CVA, Stroke): sudden, complete obstruction of blood vessel to the brain.

2 Jan 2010 . The present study was aimed at investigating the effect of the various fractions of hydromethanol extract of the leaves of *Coccinia grandis* (Cucurbitaceae) against ethanol-induced cerebral oxidative stress in rats. The leaves of this species is used in traditional medicine for treating jaundice, bronchitis, skin.

ole entit`a e di conseguenza a grandi deformazioni che si sviluppano lentamente nel tempo.

Finora lo studio meccanico di ... 2.5 Brain. The brain is a large soft mass of nervous tissue and can be divided structurally and functionally into five parts: • cerebrum,. • cerebellum,. • midbrain,. • pons,. • medulla oblongata. as one.

Objectives: The aims of this study include the following: to determine the effect of therapeutic hypothermia (Cooling) on cerebral saturations using Near Infrared Spectro..

Shy, humble, patient Giuseppe Quintarelli's focus is on the important, traditional red wines of Valpolicella, namely, Amarone and Recioto. His wines have become the canon by which all other Amarone and Recioto are judged. Quintarelli wines are complex, multifaceted, cerebral, enthralling, and much more. There is no.

S. Morotti, M. Nieves-Cintrón, M.A. Nystoriak, M.F. Navedo, E. Grandi.

Hyperglycemia-induced L-type Ca channel stimulation outweighs K channel suppression to impair intracellular calcium and vascular reactivity of cerebral arteries. Channels (Austin).

2017 Jul 4;11(4):340-346. · N.C. Surdo, M. Berrera,

investigate differences between cerebral oxygenation in different . Cerebral oxygenation in stable preterm and term neonates seems not to differ between different regions of the brain during the early neonatal period. However, variability of ... Ancora G, Maranella E, Aceti A, Pierantoni L, Grandi S, Corvaglia L, Faldella G.

28 nov. 2017 . L'ÉPHÉMÈRE SAGA OU COMMENT J'AI GRANDI (Théâtre) - du mardi 28 novembre 2017 au vendredi 8 décembre 2017 - Loge, Paris, 75011 - Toute l'info sur l'événement.

8 Aug 2009 . Cerebral blood flow is impaired by decreased formation of NO from endothelial cells, autonomic nitrergic nerves, or brain neurons and also by increased production of reactive oxygen species (ROS). The NO–ROS interaction .. Folin M, Baiguera S, Guidolin D, Di Liddo R, Grandi C, De Carlo E, et al.. 2006.

28 Jun 2015 . Purpose: Hand disability is a characteristic problem in hemiplegic cerebral palsy children which leads to limitation in . Subjects: Thirty hemiplegic cerebral palsy children (8–12 years) were randomized to two equal groups, study group and .. application as appropriate (Grandi et al., 2012). 4-Data Analysis.

A pilot cohort study of cerebral autoregulation and 2-year neurodevelopmental outcomes in neonates with hypoxic-ischemic encephalopathy who received therapeutic hypothermia. Vera Joanna Burton Email author,; Gwendolyn Gerner,; Elizabeth Cristofalo,; Shang-en Chung,; Jacky M. Jennings,; Charlamaine Parkinson,.

1 Jan 2014 . Effect of high dose isoflurane on cerebral blood flow in macaque monkeys, Magnetic . Key Words: Dose-dependent effect, Isoflurane, Cerebral blood flow (CBF), autoregulation, non-human primate, ... [18] Detre JA, Zhang W, Roberts DA, Silva AC, Williams DS, Grandis DJ, Koretsky AP, Leigh JS. Tissue.

Children with cerebral palsy associated with periventricular leukomalacia frequently develop unprovoked epileptic seizures, with a reported incidence of 16.0% to 47%. Recently cases with early thalamic injury associated with continuous spike-waves during slow sleep syndrome (CSWSS) have been reported. The aim of.

DC Bartos, S Morotti, KS Ginsburg, E Grandi, DM Bers. The Journal of physiology 595 (7), 2253-2268, 2017. 3, 2017. Predominant contribution of L-type Cav1. 2 channel stimulation to impaired intracellular calcium and cerebral artery vasoconstriction in diabetic hyperglycemia. S Morotti, M Nieves-Cintrón, MA Nystoriak, MF.

14 Jan 2015 . provided the original author and source are credited. Cerebral Metastasis of a Malignant Pleural. Mesothelioma: A Case Report and Review of the Literature. Aswin Chari , Angelos G. Koliass , Kieren Allinson , Thomas Santarius. 1. Division of Brain Sciences, Faculty of Medicine, Imperial College London 2.

11 Jul 2014 . Liu J, Kou Z, Tian Y. Diffuse axonal injury after traumatic cerebral microbleeds: an evaluation of imaging techniques. .. Zhou CP, Yang LT, Liao XY, Wang LQ, Zhu DH, Chen LS (2014a) Effects of granulation on organic acid metabolism and its relation to mineral elements in Citrus grandis juice sacs.

1 Oct 2002 . A comprehensive technique was developed for using three-dimensional ¹⁷O magnetic resonance spectroscopic imaging at 9.4T for rapidly imaging the cerebral metabolic rate of oxygen consumption (CMRO₂) in the rat brain during a two-min inhalation of ¹⁷O₂. The CMRO₂ value (2.19 ± 0.14 μmol/g/min,.

J Ethnopharmacol 109(3):547–551 Umamaheswari M, Chatterjee TK (2009) Effect of the fractions of Coccinia grandis on ethanol-induced cerebral oxidative stress in rats. Pharmacog Res 1(1):25–34 Vadivu R, Krithika A, Biplab C, Dedeepya P, Shoeb N, Lakshmi KS (2008) Evaluation of hepatoprotective activity of the fruits.

intracellular calcium and cerebral artery vasoconstriction in diabetic hyperglycemia. Stefano Morotti , Madeline Nieves-Cintrón , Matthew A. Nystoriak y. , Manuel F. Navedo yy. , and Eleonora Grandi yy. Department of Pharmacology, University of California, Davis, CA, USA. ARTICLE HISTORY. Received 31 January 2017.

Regional Cerebral Metabolic Correlates of WASO During NREM Sleep in Insomnia. Eric A. Nofzinger, M.D.¹; Christoph Nissen, M.D.^{1,3}; Anne Germain, Ph.D.¹; Douglas Moul, M.D.¹; Martica Hall, Ph.D.; Julie C. Price, Ph.D.²; Jean M. Miwald, B.A.¹; Daniel J. Buysse, M.D.¹.

¹Department of Psychiatry and ²Department of.

putidius multo cerebrum est, mihi crede, Perelli dictantis, quod tu numquam rescribere possis. (SERMONVM Q. HORATI FLACCI, SECVNDVS, 03 3:51). (□□□□□□ □□, 2□, 03□ 3:51). Abire hinc ni properas grandi gradu, iam hercle ego istos fictos compositos crispos

cinnos tuos unguentatos usque ex cerebro.

26 Jan 2014 . curing eczema, tongue sores and cerebral oxidative stress.11. Coccinia grandis contain important raw material for drug production like bioactive compounds such as secondary metabolite like alkaloids, glycoside and saponin, b- amyryne, lupeol, cucubbitacin, cephalandrol, cephalandrine and flavonoids.

“Vascular” artifacts can have substantial effects on human cerebral blood flow values calculated by using arterial spin tagging approaches. One vascular artifact arises from the contribution of “tagged” arterial water spins to the observed change in brain water MR signal. This artifact can be reduced if large bipolar gradients.

Riccardo Della Nave a, Andrea Ginestroni a, Carlo Tessa b, Elena Salvatore c, Domenico De Grandis d, Rosaria Plasmati e . Focal atrophy of the cerebral subcortical WM was also present. Histogram analysis . pronounced and combined with mild increase of the MD in the cerebral hemispheres in SCA2. In SCA1 and.

cerebral infarction with transient signs (CITS) may be a usual finding in patients with ICA occlusion who suffer isolated TIAs. In these cases, CITS may correspond to incomplete cerebral necrosis related to a well- developed collateral ... Perrone P, Candelise L, Scotti G, De Grandi D, Scialfa G: CT evaluation in patients with.

Born with cerebral palsy, Nujeen Mustafa spent most of her life in an Aleppo apartment—until she made the 3500-mile (5632 km) journey to Germany.

Detailed data for Mitsubishi Grandis Elegance 2.0 5dr MPV. The chart below provides detailed measurements and other features of this car. Where applicable, we show how this car compares to others in our database: 'Min' is the lowest value of any of the cars we list; 'Max' is the highest. Note that you can click on the.

lesions on cerebral magnetic resonance imaging scans of 64 formerly eclamptic, 74 formerly preeclamptic, .. VOL. 123, NO. 4, APRIL 2014. Wiegman et al. Cerebral Lesions After Preeclampsia and Eclampsia 791 ... Lucchini G, Grioni D, Colombini A, Contri M, De Grandi C, Rovelli A, et al. Encephalopathy syndrome in.

Read the latest articles of Perspectives in Medicine at ScienceDirect.com, Elsevier's leading platform of peer-reviewed scholarly literature.

Cerebral palsy is the most common chronic disability of childhood today. The concept of management rather than cure forms the basis of intervention. Therapy programs should be integrated with summer camps, home activities, and school, enabling the child and the family to live as close to normal as possible. Successful.

Grandis cerebrum eBook: Irati Da silva Gutiérrez: Amazon.es: Tienda Kindle.

Buy Hua Ju Hong Ba Xian Guo 化橘红, Fructus Citri Grandis For Cough Online Direct From China.It is an excellent source of Traditional Chinese medicine herbal.Any Q.

15 Sep 2009 - 4 min - Uploaded by MALLEUS ROCK ART LABReply 1. RayOddname7 years ago. Sabato aprirò il loro concerto col mio gruppo, ci stiamo .

Molecular Phylogenetic Studies Of Bitter Gourd Momordica Charantia And Ivy Gourd Coccinia Grandis And Family. Available for free Molecular Phylogenetic Studies Of Bitter Gourd . for children with cerebral palsy an evidence based approach, guaranteed ways to make 100 a day legally, its up to you overcoming erection.

Periventricular leukomalacia is the most common type of brain injury in premature infants. Our aim is to describe the frequency and the features of epilepsy in .

The exact mechanism is still unknown, but it causes the death of cerebral neurons. The average age of . Zinzi, P., D. Salmaso, R. De Grandis, G. Graziani, S. Maceroni, A.

Bentivoglio, P. Zappata, M. Frontali, and G. Jacopini, Effects of an intensive rehabilitation programme on patients with Huntington's disease: a pilot study.

Arch Neurol. 2011 May;68(5):615-21. doi: 10.1001/archneurol.2011.80. Cerebral folate deficiency syndromes in childhood: clinical, analytical, and etiologic aspects. Pérez-Dueñas B(1), Ormazábal A, Toma C, Torrico B, Cormand B, Serrano M, Sierra C, De Grandis E, Marfa MP, García-Cazorla A, Campistol J, Pascual JM.

Descargar libro gratis Grandis cerebrum, Leer gratis libros de Grandis cerebrum en España con muchas categorías de libros gratis en ePUB, PDF ebook, ePub, Mobi en Smartphones.

PRESTON | #CEREBRAL · @PrestonOff. Snap : PrestonOff • Nouveau Clip #CEREBRAL disponible : <http://po.st/Cerebral> • Premier EP 3 titres maintenant sur toutes les plateformes. po.st/CerebralEP ... @AurelieLmet j'ai aussi grandi sans père, je sais ce que c'est. C'est dure comme décision mais tu as la chance de.

1 Jul 2010 . Molecular Analysis of Plasma DNA for the Early Detection of Lung Cancer by Quantitative Methylation-Specific PCR. Kimberly Laskie Ostrow, Mohammad O. Hoque, Myriam Loyo, Marianna Brait, Alissa Greenberg, Jill M. Siegfried, Jennifer R. Grandis, Autumn Gaither Davis, William L. Bigbee, William Rom.

Abstract. ABSTRACT: Hansson, O., Kristensson, K., Lycke, E., Solymar, L. and Sourander, P. (Departments of Paediatrics II, Virology and Pathology I, University of Gothenburg, Sweden). Generalized myopathy and cerebral malformations possibly related to an enteroviral infection. Acta Paediatr Scand, 64: 881, 1975–A.

2 Nov 2012 . AQP4 is found throughout the brain but is particularly abundant in the optic nerves and spinal cord [4]. In rats, AQP4 is present on astrocytic foot processes along the endothelial tight junctions at the blood-brain barrier (BBB), on the abluminal side of cerebral microvessels, within the cerebellar Purkinje cell.

Objective: To compare the effect of electrical stimulation applied before and after botulinum toxin injection. Subjects: Eight healthy subjects. Methods: Both extensor digitorum brevis muscles were injected with low fixed doses of botulinum toxin. Subjects received a 20-min session of electrical stimulation before botu-.

19 Mar 2010 . Rudra A, Chatterjee S, Sengupta S, Iqbal A, Pal S, Wankhede R. The Child with Cerebral Palsy and Anaesthesia. . Cerebral palsy (CP) is a common cause of childhood disability. ... Fiacchino F, Grandi L, Soliveri P, Carella F, Bricchi M. Sensitivity to vecuronium after botulinum toxin administration.

Continuous arterial spin labeling (CASL) is a noninvasive magnetic resonance (MR) method for measuring cerebral perfusion. In its most widely used form, CASL incorporates a postlabeling delay to minimize the sensitivity of the technique to transit time effects, which otherwise corrupt cerebral blood flow (CBF).

Procuramos descrever casos da associação de EB e acidente vascular cerebral (AVC), analisar sua frequência, aspectos clínicos e os mecanismos envolvidos nas .. Scotti G, De Grandi C, Colombo A. Ectasia of the intracranial arteries diagnosed by computed tomography: megadolichobasilar artery CT diagnosis.

C, De Grandis E, Marfa MP, García-Cazorla A, Campistol J, Pascual JM, Artuch R. Cerebral folate deficiency syndromes in childhood: clinical, analytical, and etiologic aspects. Arch Neurol. 2011 May;68(5):615-21. doi: 10.1001/archneurol.2011.80. PubMed PMID: 21555636. Pérez-Dueñas B, Toma C, Ormazábal A, Muchart.

families of flowering plants (along with Chloranthaceae) on the basis of fossil pollen types assigned to modern families. The Cretaceous fossil pollen genus Walkeriipollis from the late Barremian – early Aptian of Gabon and the late Aptian – early Albian of Israel is winteraceous2,3. Winteraceae persisted in continental.

Although most patients with takotsubo cardiomyopathy have a favorable outcome, complications are not uncommon. Recent studies have reported an increase in incidence of

cardioembolic complications; however, the association between takotsubo cardiomyopathy and stroke, in particular thromboembolic cerebral.

In this booklet there's some business about the body and the soul, and so we ask ourselves like madmen: "But what's a body? But what's a body?" One of us explains to the other that it is a thing with muscles and cartilage, cerebrum and cerebellum, skin and balls, but who's ever seen one? It's spoken of, it's talked about, but.

1 Oct 1999 . The cerebellum seems to be affected by age (Ellis, 1920; `Sullivan et al., 1995; Raz 1997), although its volume loss is less as compared to the cerebrum. In some subject samples age effects on the cerebellum were insignificant (Hayakawa et al., 1989; Escalona et al. 1991). Inside the cerebellum, some.

Running Title: Cerebral cannabinoid-1 receptors in functional dyspepsia. Correspondence to: Lukas Van Oudenhove . and compare in vivo cerebral cannabinoid-1 (CB1) receptor availability between FD patients and age-, gender- and BMI-matched healthy .. Sirri L, Grandi S, Fava GA (2008). The Illness Attitude Scales.

Battaglia T, De Grandis E, Mirabelli-Badenier M, Boeri L, Morcaldi G, Barabino P, et al. Response to rituximab in 3 children with opsoclonus-myoclonus . Electrophysiological evidence of cerebral dysfunction in childhood opsoclonus-myoclonus syndrome. *Mov Disord* 2010;25:940-5. Wilken B, Baumann M, Bien CG, Hero B.

26 Jul 2008 . Many people like the connotations of a mode of life in which the physical vies with the cerebral for supremacy; look at the success of the smaller Nissan Qashqai, which looks like a mild SUV but is really just a .. Often overlooked, the Grandis is long and sleek and uses the same VW engine as the Dodge.

1 Jul 2007 . a) cerebral cortex involvement in motor function, b) the electrical excitability of the cortex, c) topographic .. of the cerebrum is not glandular, as many anatomists have described it, nay have positively asserted, but .. empirical work on the brain and his speculations were in the form of baroque and grandis-.

Grandis et, ut ita dicam, pudica oratio non est maculosa nec turgida, sed naturali pulchritudine exurgit. Nuper ventosa istaec et enormis loquacitas Athenas ex Asia commigravit .. Credite mihi, anathymiasis si in cerebrum it, et in toto corpore fluctum facit. Multos scio periisse, dum nolunt sibi verum dicere." Gratias agimus.

29 Jul 2013 . The oxoaporphine alkaloid lysicamine (1), and three proaporphine alkaloids, litsericinone (2), 8,9,11,12-tetrahydromecambrine (3) and hexahydromecambrine A (4) were isolated from the leaves of *Phoebe grandis* (Nees) Merr. (Lauraceae). Compounds 2 and 3 were first time isolated as new naturally.

